SonoPath
Clinical Sonography & Telecytology

EDUCATIONAL TELECONSULTATION SERVICES™

1-800-838-4268 info@sonopath.com SonoPath.com

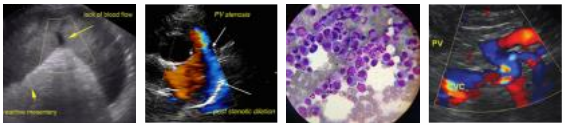

ANIMAL SOUNDS NW
MOBILE VETERINARY ULTRASOUND

IMAGING PERFORMED BY

AnimalSoundsNW.com 541-357-9423

PATIENT
Frank Garber

SPECIES
Canine

BREED
Rottweiler

SEX
Male

AGE
9 months

WEIGHT
63lbs

INTERPRETED BY
Maggie Machen Lamy, DVM, DACVIM (Cardiology)

IMAGING PERFORMED BY
Jenna Walsh, CVT

HOSPITAL NAME
Four Corners Veterinary Clinic

REFERRING VET
Dr. Williams

INVOICE
28933

DATE
2/10/23

PRESENTING CLINICAL SIGNS

History: Grade 4/6 heart murmur. Asymptomatic. BP: 76, 85, 81mmHg.
-Current medications: 600mg gabapentin, 200mg tramadol, butorphanol and ace IV all for sedation.

ELECTROCARDIOGRAPHIC FINDINGS *Note: Single lead ECGs are evaluated as a rhythm strip. Morphology/MEA cannot be definitively commented on.

A single lead ECG is available; 25mm/s, 5mm/mV. The average heart rate is 110bpm (range 94-130bpm). The rhythm is sinus in origin, with a p for every QRS complex and vice versa. The P and QRS morphologies are positive. No ectopic beats, pauses or dysrhythmias observed.
ECG diagnosis: Normal sinus rhythm with respiratory variation.

ECHOCARDIOGRAM FINDINGS

2D, m-mode, color flow and doppler imaging is available. The left ventricular wall is moderate to severely hypertrophied (1.9cm globally). There is a diffusely hyperechoic endocardium consistent with fibrosis. Papillary muscle hypertrophy. The left atrium is mildly enlarged. The right atrium is normal in size. The right ventricle appears normal. The mitral valve is dysplastic, with an elongated and thickened anterior leaflet that prolapses into the LVOT in systole. There is mild anterior-directed mitral regurgitation associated with this abnormal motion. Normal velocity. Trace tricuspid regurgitation seen. Normal velocity. Blood flow through the LVOT is severely increased, suspected to be falsely underestimated due to sedation. Significant subaortic narrowing is seen. The aortic valve appears mildly thickened. Mild aortic insufficiency. Trace PI. Normal RVOT velocity. Prominent coronary vessels. No obvious shunts. No evidence of cardiac tumors or metastatic lesions on this scan. No pleural or pericardial effusion seen.

CARDIAC CHART

CANINE CARDIAC PARAMETERS	MR VMAX (m/s)	TR VMAX (m/s)	LA/AO (Boon method)	LA/AO (Heart Base; Swe)	FS (%)	EF (%)	EPSS (cm)
NORMAL PARAMETER	4.5-5.5	<2.7	1.3	<1.6	28-40	40-100	<0.6
PATIENT	4.2	2.7	1.3	1.5	43	75	0.3
CANINE CARDIAC PARAMETERS	**HR** (BPM)	**AV VMAX** (m/s)	**PV MAX** (m/s)	**BODY WEIGHT** (kg)	**LA** 2D short axis Base view (cm)	**LVIDd** Avg; 2D and m-mode short axis (cm)	**LVIDs** Avg; 2D and m-mode short axis (cm)
NORMAL PARAMETER	50-100	0.7-1.7	0.7-1.6	BELOW	BELOW	BELOW	BELOW
PATIENT	90	4.9	1.2	28.6	2.7	3.7	2.1
*Normal chamber parameters expressed as a mean value (SD)				3	1.27 (5.3)	2.46 (2.46)	1.36 (5.5)
BODY WEIGHT DEPENDENT PARAMETERS				5	1.40 (4.5)	2.74 (5.2)	1.60 (4.7)
				10	1.50 (3.8)	3.27 (3.5)	2.06 (3.1)
Adapted from June Boon, Veterinary Echocardiography, 1998				15	1.83 (2.0)	3.71 (2.4)	2.43 (2.1)
Rishniw M and Hollis NE, J Vet Intern Med 2000; 14:429-435				20	2.02 (1.9)	4.14 (2.2)	2.80 (2.0)
Hansson et al, Vet Rad and Ultrasound 2002				25	2.18 (2.4)	4.48 (2.9)	3.10 (2.5)
Bonagura et al. Echocardiography: principles of interpretation, Vet				30	2.33 (3.3)	4.83 (3.9)	3.39 (3.4)

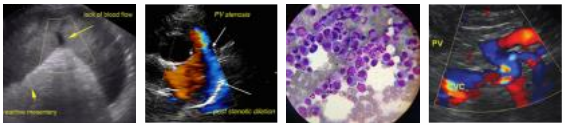

PATIENT
Frank Garber

SPECIES
Canine

BREED
Rottweiler

SEX
Male

AGE
9 months

WEIGHT
63lbs

INTERPRETED BY
Maggie Machen Lamy, DVM, DACVIM (Cardiology)

IMAGING PERFORMED BY
Jenna Walsh, CVT

HOSPITAL NAME
Four Corners Veterinary Clinic

REFERRING VET
Dr. Williams

INVOICE
28933

DATE
2/10/23

Clin North Am 15:1177, 1995	35	2.48 (4.3)	5.17 (5.0)	3.69 (4.5)
	40	2.62 (5.2)	5.48 (6.1)	3.96 (5.4)
	50	2.88 (7.1)	6.07 (8.3)	4.46 (7.4)

INTERPRETATION OF THE FINDINGS & FURTHER RECOMMENDATIONS

The cause of the murmur is increased flow velocity through the LVOT and aortic valve. First, there is mitral valve dysplasia with secondary LVOT obstruction and mitral regurgitation present. This is similar to SAM in a cat, with hypertrophy of the LV secondary to pressure overload caused by obstruction to flow. This type of obstruction tends to be heart rate dependent, with a dynamic profile. There is also sub-aortic component suspected, due to the appearance of the LVOT. Finally, the aortic valve also appears thickened, likely reflecting a primary valvular issue and mild AI. There is severe LV hypertrophy present indicating pressure overload and mild left atrial dilation. Mitral stenosis remains a possibility and is not ruled out in this image set. No additional defects are seen; however, it should be mentioned that small defects/shunts are easily missed in congenital echocardiography. No evidence of volume overload or other secondary changes. Highly recommend referral in this case due to multiple abnormalities appreciated and need for lifelong monitoring.

The ECG is unremarkable with a normal sinus rhythm.

Lifelong heart rate control with atenolol is recommended, as the dynamic nature of the obstruction will be reduced at lower heart rates. No other medications are indicated at this juncture. Monitor for development of labored breathing, exercise intolerance or collapse episodes, as SAS/AS patients are more predisposed to development of arrhythmias than to CHF. Mild exercise restriction is advised lifelong.

Prognosis is guarded yet highly variable, with many severe AS/SAS patients succumbing by mid-life. My main concern in this case is the young age of the patient with severe hypertrophy already present. Follow up is highly recommended.

Once Atenolol is initiated, anesthetic risk is mild. Avoid heart rate stimulating drugs such as atropine or glycopyrrolate unless clinically indicated. Avoid ketamine and acepromazine due to systemic vascular effects. Mild IV fluid restriction is advised. Recommend prophylactic antibiotics for any orthopedic or dental procedure in the future given predisposition to endocarditis.

PLAN

Recommend referral for lifelong monitoring. Administer titrating dose of atenolol: 25mg tablets; Give ¼ tab once daily. Recheck heart rate in 1-2 weeks with target stressed rate of <140bpm, Increase as needed until target reached. Will need to up-titrate to desired effect as puppy grows.

Recommend recheck echocardiogram in 6-12 months to assess response to atenolol and screen for small concurrent defects, sooner if clinical issues arise.

SonoPath
Clinical Sonography & Telecytology
EDUCATIONAL TELECONSULTATION SERVICES™
1-800-838-4268 info@sonopath.com SonoPath.com

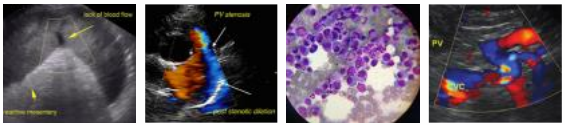

ANIMAL SOUNDS NW
MOBILE VETERINARY ULTRASOUND
IMAGING PERFORMED BY
AnimalSoundsNW.com 541-357-9423

PATIENT
Frank Garber

SPECIES
Canine

BREED
Rottweiler

SEX
Male

AGE
9 months

WEIGHT
63lbs

INTERPRETED BY
Maggie Machen Lamy, DVM, DACVIM (Cardiology)

IMAGING PERFORMED BY
Jenna Walsh, CVT

HOSPITAL NAME
Four Corners Veterinary Clinic

REFERRING VET
Dr. Williams

INVOICE
28933

DATE
2/10/23

IMAGES

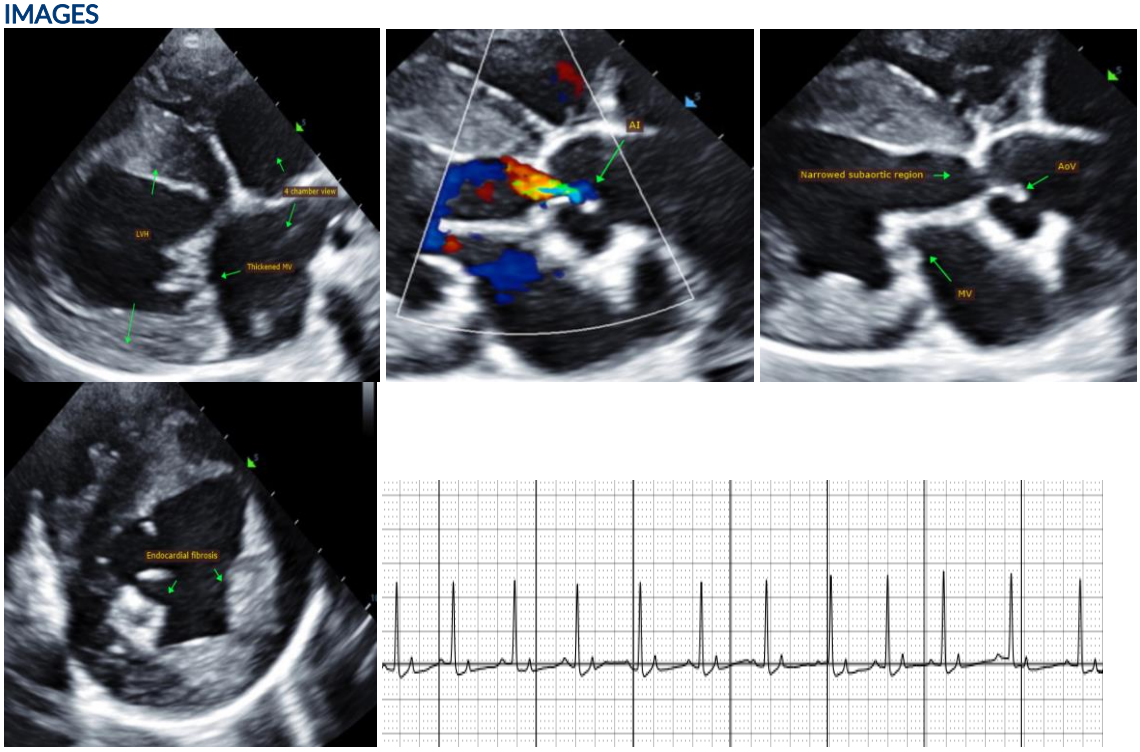

The information and recommendations provided are based on the images presented by the referring veterinarian. No evaluation can be communicated regarding pathology that was not visible in the image/video clips provided.

Thank you for this referral. This report was generated using transcription software, and minor dictation errors may be present. If the clinical or image interpretation does not parallel your findings or if I can be of any further assistance please contact me.

Maggie Machen Lamy, DVM
Diplomate of the American College of Veterinary Internal Medicine (Cardiology)
info@sonopath.com